

Periacetabular Osteotomy

A Systematic Literature Review

John C. Clohisy MD, Amanda L. Schutz PhD, MPA,
Lauren St. John BS, Perry L. Schoenecker MD,
Rick W. Wright MD

Received: 18 June 2008 / Accepted: 3 April 2009 / Published online: 21 April 2009
© The Association of Bone and Joint Surgeons 2009

Abstract The Bernese periacetabular osteotomy is commonly used to treat symptomatic acetabular dysplasia. Although periacetabular osteotomy is becoming a more common surgical intervention to relieve pain and improve function, the strength of clinical evidence to support this procedure for these goals is not well defined in the literature. We therefore performed a systematic review of the literature to define the level of evidence for periacetabular osteotomy, to determine deformity correction, clinical results, and to determine complications associated with the procedure. Thirteen studies met our inclusion criteria. Eleven studies were Level IV, one was Level III, and one was Level II. Radiographic deformity correction was consistent and improvement in hip function was noted in all studies. Most studies did not correlate radiographic and clinic outcomes. Clinical failures were commonly associated with moderate to severe preoperative osteoarthritis

and conversion to THA was reported in 0% to 17% of cases. Major complications were noted in 6% to 37% of the procedures. These data indicate periacetabular osteotomy provides pain relief and improved hip function in most patients over short- to midterm followup. The current evidence is primarily Level IV.

Level of Evidence: Level IV, therapeutic study. See Guidelines for Authors for a complete description of levels of evidence.

Introduction

Developmental dysplasia of the hip with associated structural instability is one of the more common causes of secondary osteoarthritis [1, 11]. Patients frequently present in adolescence or young adulthood with prearthritic hip symptoms related to structural instability and acetabular rim overload [13]. When left untreated, this structural abnormality can be associated with progressive hip degeneration and eventual end-stage disease [20]. Specifically, Murphy et al. [20] noted, in a series of dysplastic hips followed over time, no patient had a well-functioning hip at the age of 65 years if the lateral center-edge angle was less than 16°, the acetabular index of depth to width was less than 38%, the acetabular index was greater than 15°, uncovering of the femoral head was greater than 31%, or the peak to edge distance was zero. Given this known correlation with secondary osteoarthritis, various corrective hip osteotomy techniques have been proposed for the treatment of symptomatic dysplasia. These procedures include innominate osteotomies [24, 28], juxtaarticular triple osteotomies [29], periacetabular osteotomies (PAOs) [9], and spherical osteotomies [21, 33]. The goals of surgical treatment are to correct the hip pathomechanics, relieve symptoms, maintain

This work was supported in part by Award Number UL1RR024992 from the National Center For Research Resources (JCC). The content is solely the responsibility of the authors and does not necessarily represent the official views of the national Center for Research Resources or the National Institutes of Health. This work was also supported in part by the Curing Hip Disease fund (JCC). One or more of the authors (JCC) has received clinical research support from a Zimmer, Inc, Clinical Research Grant. This work was performed at Washington University School of Medicine.

J. C. Clohisy (✉), A. L. Schutz, L. St. John, R. W. Wright
Department of Orthopaedic Surgery, Washington University
School of Medicine, One Barnes-Jewish Hospital Plaza,
Suite 11300 West Pavilion, Campus Box 8233, St Louis,
MO 63110, USA
e-mail: clohisj@wudosis.wustl.edu

P. L. Schoenecker
Shriners' Hospital for Children, St Louis, MO, USA

or improve patient activity and quality of life, delay or prevent secondary osteoarthritis, and preserve the natural hip with time.

The Bernese PAO was developed as a reconstructive pelvic osteotomy technique by Ganz et al. [9] and is now commonly used as a surgical treatment for symptomatic acetabular dysplasia [2–7, 15, 17–19, 23, 27, 30, 31]. The PAO reorients the acetabulum to reduce superolateral acetabular inclination, improve femoral head coverage, translate the joint center medially, and normalize loading of the anterolateral acetabular rim [16]. Although PAO is being performed more frequently, the strength of clinical evidence to support the efficacy of this procedure is not clearly defined in the literature.

There are four major purposes of this study: (1) to determine the level of evidence regarding PAO; (2) assess deformity correction; (3) analyze clinical results; and (4) review the reported complications for this procedure.

Materials and Methods

We searched PubMed, CINAHL[®], and the Cochrane Library for articles published between January 1950 and February 2008. We also searched EMBASE[™] for articles

published between 1980 and 2008. CINAHL[®] and the Cochrane Library were searched July 30, 2007; EMBASE[™] and PubMed were searched August 10, 2007. All databases were searched again on February 25, 2008, to identify additional articles. Database search terms included: “periacetabular osteotomy,” “Bernese osteotomy,” and “Ganz osteotomy.” Each term was searched individually and then combined with “hip dysplasia.” These were the only terms searched for this study. We also hand-searched the following journals for articles published between November 2007 and February 2008: *Clinical Orthopaedics and Related Research*, *Journal of Bone and Joint Surgery (British and American Volumes)*, *Acta Orthopaedica*, *Journal of Arthroplasty*, and *International Orthopaedics*. Bibliographies of the included studies also were searched to screen for additional studies. Search results were entered in EndNote[®] to remove duplicate studies. A total of 235 articles were identified in our search and each abstract underwent review by two of the authors (ALS, LSJ) (Fig. 1). We included only studies that were peer-reviewed, published in English, reported clinical and radiographic outcomes of the Bernese PAO, and had a minimum of 2 years’ followup. Of the 235 articles, 44 met inclusion criteria. We excluded articles if they were case reports or reviews, investigated femoroacetabular

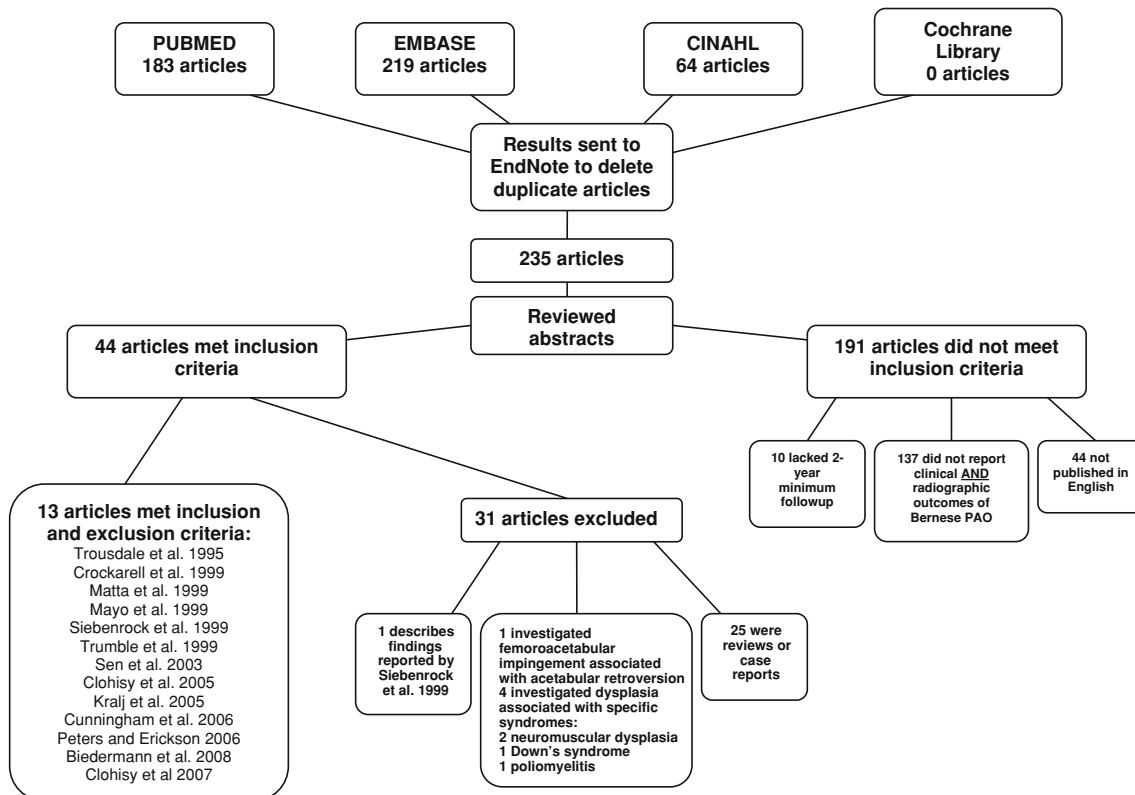


Fig. 1 A flow diagram illustrates the method of article selection for study inclusion.

impingement associated with acetabular retroversion or dysplasia associated with specific syndromes (neuromuscular dysplasia, Down's syndrome, and poliomyelitis), or if they described previously reported findings. Of 235 articles, 13 met the inclusion criteria and were analyzed in this review (Table 1). Each article underwent review by three of the authors (JCC, ALS, LSJ). The authors identified potential biases that may have affected the quality of conclusions. Items reviewed included study type, groups in study, inclusion and exclusion criteria, outcome measures, clinically important findings, independent assessment, power, confidence interval, statistics used, potential bias, and level of evidence. Any differences noted between the three reviewers were discussed and consensus was reached regarding the item in question.

The method of reporting of clinical outcomes and failures varied among the studies. Clinical outcome measures of each study are summarized. Clinical failures are reported using the criteria of each study but also reported using the objective end point of conversion to THA (Table 2). When reported, radiographic and range of motion findings were documented in consistent fashion (Tables 3, 4).

The method of reporting complications varied widely among studies. Therefore, we have summarized the complications as reported in each study and also graded the complications into major, moderate, and minor categories (Table 5). We used the previous grading system of Davey and Santore [8] with some modification and expansion to categorize all the complications reported. Major complications include deep vein thrombosis, major arterial thrombosis (iliac/femoral), major vessel laceration (iliac/femoral), pulmonary embolism, symptomatic or clinically important (limitation of hip motion) heterotopic ossification, lateral femoral cutaneous nerve dysfunction requiring surgery, femoral/sciatic nerve dysfunction, intraarticular osteotomies, intraarticular fracture, hematomas and infection requiring surgery, femoral head resubluxation requiring surgery, major blood loss, femoral head and acetabular osteonecrosis, posterior column discontinuity, malreduction requiring revision osteotomy, any nonunion requiring bone grafting, and loss of acetabular fixation requiring reoperation. Moderate complications consisted of: symptomatic hardware (with or without surgical removal), ischial fracture or posterior column fracture not requiring surgery, hematoma with unspecified or nonsurgical treatment, and mildly symptomatic nonunion not requiring surgery. Minor complications included asymptomatic or minimal heterotopic ossification, asymptomatic pubic nonunion, superficial infection not requiring surgery, lateral femoral cutaneous nerve dysfunction or dysesthesias not requiring intervention, and miscellaneous (urinary tract infection, postoperative fever, etc).

Results

The level of evidence for PAO is low, with 11 of the 13 articles being Level IV (Table 1). The report by Cunningham et al. [7] is a Level II prognostic study assessing the value of the preoperative dGEMRIC index in identifying poor candidates for PAO. The dGEMRIC index was calculated as the average of the T1 values of the acetabular and femoral head cartilages in the weightbearing zone across all four coronal slices [12]. Cunningham et al. [7] concluded patients whose hips have severely diminished joint space, higher Tönnis grade (2 or 3), joint subluxation, or lower dGEMRIC index are less likely to benefit from this procedure. Mayo et al. [18] published a Level III retrospective study comparing patients treated with PAO after a previous hip osteotomy with patients without previous hip osteotomy surgery. They observed no clinical differences between these two groups. No additional Levels I, II, or III studies were identified with our review of the literature.

These data derived from various surgeons and institutions indicate PAO can reliably achieve deformity correction (Table 3). The mean change in acetabular inclination ranged from 4.5° to 25.9°. Similarly, the mean changes in anterior and lateral center-edge angles ranged from 16° to 51° and 20° to 44.6°, respectively. The procedure also provides medial translation of the hip center, with an average change ranging from 5 mm to 10 mm. The magnitude of deformity correction is dependent on the underlying severity of deformity. Clohisy et al. [3] reported the largest corrections in the treatment of severely dysplastic hips. The majority of articles made no attempt to correlate radiographic correction with clinical results.

Clinical outcome analysis showed pain relief and improved hip function in the majority of patients at short- to midterm followup (Table 2). The Harris hip score was the most commonly used outcome measure (eight of 13 studies). All eight studies reported improvements in the average Harris hip score, with mean improvements ranging from 14.5 to 33 points. Seven studies correlated more advanced preoperative osteoarthritis with suboptimal clinical results. Alternatively, improved hip function was most predictable for hips with little or no preoperative osteoarthritis. Failure of the osteotomy with conversion to THA was noted in 0% to 17% of the cases. Additionally, the osteotomy was associated with decreased hip range of motion (flexion, abduction, internal rotation) (Table 4).

Major complications were common and occurred in 6% to 37% of cases. The most common major complications included symptomatic heterotopic ossification, wound hematomas, nerve palsies, intraarticular osteotomies, loss of fixation, and malreductions. The most common moderate complication was symptomatic hardware requiring

Table 1. Participant demographics for studies of periacetabular osteotomy

Study	Study design, level of evidence	Bias	Hips/patients	Female:male	Followup (years)*	Percent followup	Years of investigation	Age (years)*	Unique features of cohort	Previous surgery
Trousdale et al. [30] (1995)	Retrospective case series, IV	NA	42/42	34:8	4 (2–8)	100%	1984–1990	37 (11–56)	NA	14 (33%)
Crockarell et al. [6] (1999)	Retrospective case series, IV	NA	21/19	14:5	3.2 (2–4.3)	100%	1992–1995	21 (17–43)	NA	6 (32%)
Matta et al. [17] (1999)	Retrospective case series (prospectively collected), IV	NA	66/58	42:16	4 (2–10)	100%	1987–1996	33.6 (19–51)	NA	12 (18%)
Mayo et al. [18] (1999)	Retrospective comparative study (prospectively collected), III	NA	19/18	10:8	3.8 (2.2–7.1)	100%	1988–1998	30.9 (17–49)	All hips with previous hip osteotomy	19 (100%)
Siebenrock et al. [27] (1999)	Retrospective case series, IV	NA	71/63	58:17	11.3 (10–13.8)	95%	1984–1987	29 (13–56)	NA	23 (31%)
Trumble et al. [31] (1999)	Retrospective case series, IV	NA	123/115	79:36	4.3 (2–10)	99%	1988–1998	32.9 (14–54)	NA	26 (21%)
Sen et al. [26] (2003)	Retrospective case series, IV	NA	23/22	NA	3.4 (2–5.5)	100%	NA	23.1 (15–38)	All hips with acetabular dysplasia; ½ of patients treated with Kotz osteotomy and ½ with Ganz osteotomy	4 (18%)
Clohisy et al. [3] (2005)	Retrospective case series, IV	NA	16/13	11:2	4.3 (2–8.1)	100%	1994–2001	17.6 (13–31.8)	All hips with severe acetabular dysplasia	3 (19%)
Kralj et al. [15] (2005)	Retrospective case series (prospectively collected), IV	Recall	26/26	22:4	1.2 (7–15)	100%	1987–1995	34 (18–50)	NA	NA
Cunningham et al. [7] (2006)	Prospective cohort study, II	Possible selection	52/47	41:6	2.9 (2–3.8)	100%	1999–2002	30 (11–45)	NA	NA
Peters and Erickson [23] (2006)	Retrospective case series (prospectively collected), IV	Possible selection	83/73	55:18	3.8 (2.5–7.3)	100%	1997–2003	28 (15–47)	NA	9 (12%)
Biedermann et al. [2] (2008)	Retrospective case series, IV	NA	60/50	36:14	7.4 (2.1–12.5)	84%	1988–1998	27.3 (12–44)	NA	NA
Clohisy et al. [5] (2007)	Retrospective case series, IV	NA	24/20	11:9	4.5 (2–9.3)	100%	1994–2003	22.7 (13–44)	All hips with associated major femoral head deformities	12 (50%)

* Values expressed as means, with ranges in parentheses; NA = data not available.

Table 2. Surgical techniques and outcomes reported from studies evaluating periacetabular osteotomy

Study	Hips/ patients	PAO isolated	PAO with other	Clinical outcome scores	Number clinically good or excellent outcome	Change in hip score* (points)	Failure definition	Failure	Conversion to THA, average months post-PAO	Radiographic osteoarthritis progression
Trousdale et al. [30] (1995)	42/42	32 hips (76%)	10 hips (24%)	HHS	32 hips (97%) with Tönnis Grade 1 or 2	24 (62–86)	Subsequent major surgery	9 (21%)	6 (14%)	14 (10%)
Crockarell et al. [6] (1999)	21/19	15 patients (79%)	4 patients (21%)	Mayo Hip Score, HHS	NA	Mayo 22 (46–68), HHS 24 (62–86)	Conversion to THA	1 (5%)	1 (5%)	2 (10%)
Matta et al. [17] (1999)	66/58	56 hips (85%)	10 hips (15%)	Merle D’Aubigné	50 hips (77%)	NA	Conversion to THA or end-stage arthrosis awaiting reconstructive surgery	8 (12%)	5 (6%), 85.2	22 (33%)
Mayo et al. [18] (1999)	19/18	5 hips (26%)	14 hips (74%)	Merle D’Aubigné, HHS	NA	Merle D’Aubigne 3.3 (13.1–16.4), HHS 30 (60–90)	Conversion to THA or HHS < 80 and Merle d’Aubigne score < 16	4 (21%)	2 (11%), 42.5	2 (11%)
Siebenrock et al. [27] (1999)	71/63	47 patients (75%)	16 patients (25%)	Merle D’Aubigné	52 hips (73%)	1.7 (14.6–16.3)	Conversion to THA or fusion	13 (18%)	12 (17%), 73.2	14 (20%)
Trumble et al. [31] (1999)	123/115	90 hips (73%)	33 hips (27%)	Merle D’Aubigné, HHS	102 hips (83%)	Merle D’Aubigne 2.7 (13.5–24.4), HHS 24 (64–87)	Clinical failure	21 (17%)	7 (6%), 41	6 (5%)
Sen et al. [26] (2003)	23/22	NA	NA	HHS	NA	14.5 (–5–25)	NA	NA	NA	3 (13%)
Clohisy et al. [3] (2005)	16/13	10 hips (62%)	6hips (38%)	HHS	14 hips (88%)	17.9 (73.4–91.3)	Dissatisfied with result of surgery	2 (13%)	0 (0%)	5 (31%)
Kralj et al. [15] (2005)	26/26	NA	NA	NA	16 hips (62%)	NA	Conversion to THA	4 (15%)	4 (15%), 54	8 (31%)
Cunningham et al. [7] (2006)	52/47	NA	NA	WOMAC (pain)	42 (81%)	6.1 (7.3–1.2)	Conversion to THA, increased pain, or increased joint space narrowing	10 (19%)	5 (10%)	9 (17%)
Peters and Erickson [23] (2006)	83/73	83%	17%	HHS	NA	33 (55–88)	Conversion to THA or revision osteotomy	4 (5%)	3 (4%), 36	26 (31%)
Biedermann et al. [2] (2008)	60/50	33 patients (66%)	17 patients (34%)	WOMAC, SF-36	NA	NA	Conversion to THA or arthrodesis	0 (0%)	0 (0%)	17 (28%)
Clohisy et al. [5] (2007)	24/20	9 hips (37%)	15 hips (63%)	HHS	19 hips (79%)	22.5 (68.8–91.3)	Dissatisfied with result of surgery	1 (5%)	0 (0%)	4 (17%)

* Values expressed as means, with ranges in parentheses; PAO = periacetabular osteotomy; HHS = Harris hip score; NA = data not available.

Table 3. Radiographic outcomes reported from studies evaluating the periacetabular osteotomy

Study	Mean change in acetabular inclination	Mean anterior center-edge angle correction	Mean lateral center-edge angle correction	Medial translation of joint center correction (mm)
Trousdale et al. [30] (1995)	20°	26°	28°	5
Crockarell et al. [6] (1999)	13°	44°	22°	NA
Matta et al. [17] (1999)	21.8°	NA	28°	6.2
Mayo et al. [18] (1999)	18°	21°	24°	6
Siebenrock et al. [27] (1999)	20°	22°	28°	6
Trumble et al. [31] (1999)	17°	25°	23°	5
Sen et al. [26] (2003)	NA	36.3°	37.9°	NA
Clohisy et al. [3] (2005)	25.9°	51.0°	44.6°	10
Kralj et al. [15] (2005)	NA	16°	22°	5
Cunningham et al. [7] (2006)	18°	25°	27°	NA
Peters and Erickson [23] (2006)	Group 1: 20° Group 2: 17°	Group 1: 26° Group 2: 21°	Group 1: 26° Group 2: 20°	NA
Biedermann et al. [2] (2008)	4.5°	NA	22.8°	NA
Clohisy et al. [5] (2007)	16.5°	33.1°	27.6°	6.3

NA = data not available.

Table 4. Range of motion outcomes reported from studies evaluating periacetabular osteotomy

Study	Reduction of flexion	Reduction of abduction	Reduction of adduction	Reduction of external rotation	Reduction of internal rotation
Trousdale et al. [30] (1995)	12°	6°	6°	6°	5°
Crockarell et al. [6] (1999)	15°	6°	6°	21°	21°
Siebenrock et al. [27] (1999)	18°	6°	3°	8°	13°

removal. Eight of the studies acknowledged the substantial learning curve associated with this surgical procedure (Table 5), suggesting the complication rate may diminish with increased experience.

Discussion

The PAO is one of the preferred reconstructive osteotomies for treatment of symptomatic acetabular dysplasia. Nevertheless, the clinical evidence to support this procedure and the efficacy of the procedure on large patient cohorts has not been reported. The purpose of this study was to determine the level of clinical evidence regarding PAO and to analyze the procedure relative to deformity correction, clinical results, and complications.

The literature limitations are substantial and stem from the heterogeneous data collection methods used in these retrospective studies. For example, diverse outcome measures included in the different studies make interpretation difficult. Similarly, the definitions of treatment failure and indications for surgery varied among studies.

Certain important aspects of this procedure could not be addressed by this systematic review. For example, we have summarized complications associated with PAO, yet the reporting methods in individual studies were inconsistent. To lend objectivity to this review, we categorized complications according to guidelines modified from Davey and Santore [8]. With this analysis, the observed major complication rate ranged from 6% to 37%. This relatively high complication rate likely reflects the complexity of the procedure combined with the surgeon learning curve effect. It is likely the majority of the studies represent the learning curve experience of the involved surgeon(s), and eight of the reports discussed the potential for a higher complication rate during the surgeon's learning curve experience. It is possible, as joint preservation surgeons gain additional experience in patient selection for surgery, surgical technique, and the appropriate role of adjunctive procedures, the clinical results and survivorship may improve. Certainly, future multicenter studies with large numbers of patients are needed to define the incidence and characteristics of complications associated with the procedure.

Table 5. Complications reported from studies evaluating the periacetabular osteotomy

Study	Subsequent major surgical procedures other than THA	Major complications	Moderate complications	Minor complications	Learning curve
Trousdale et al. [30] (1995)	1 (2%) excision of heterotopic ossification 1 (2%) LFCN neurolysis 1 (2%) labral resection 1 (2%) extension PFO 2 (5%) varus PFO Total: 6 (14%)	2 (5%) DVT 1 (2%) symptomatic heterotopic ossification 1 (2%) LFCN dysesthesias (requiring neurolysis) Total: 4 (10%)	9 (21%) symptomatic hardware Total: 9 (21%)	13 (31%) asymptomatic heterotopic ossification 2 (5%) pubic nonunion (no surgery) Total: 15 (36%)	Not discussed
Crockarell et al. [6] (1999)	1 (5%) PFO 1 (5%) acetabular rim trimming Total: 2 (10%)	3 (15%) peroneal nerve dysfunction 2 (10%) intraarticular osteotomies Total: 5 (24%)	3 (14%) ischial fracture Total: 3 (14%)	3 (14%) asymptomatic pubic nonunion 5 (24%) asymptomatic heterotopic ossification 1 (5%) superficial infection Total: 9 (43%)	Not discussed
Matta et al. [17] (1999)	2 (3%) excision heterotopic ossification Total: 2 (10%)	5 (8%) heterotopic ossification limiting flexion 2 (3%) loss of fixation with associated iliac nonunion Total: 7 (12%)	7 (12%) symptomatic hardware Total: 7 (12%)	1 (2%) LFCN dyesthesias 11 (17%) asymptomatic pubic nonunion 4 (6%) heterotopic ossification Total: 16 (24%)	Authors acknowledge a significant learning curve
Mayo et al. [18] (1999)	1 (5%) PFO 1 (5%) surgical hip dislocation Total: 2 (11%)	2 (11%) hematoma requiring surgical treatment Total: 2 (11%)	5 (28%) symptomatic hardware 2 (11%) hematoma Total: 7 (37%)	3 (16%) heterotopic ossification (Brooker Class I) 5 (26%) LFCN dysfunction Total: 8 (42%)	Not discussed

Table 5. continued

Study	Subsequent major surgical procedures other than THA	Major complications	Moderate complications	Minor complications	Learning curve
Siebenrock et al. [27] (1999)	3 (4%) revision osteotomy 2 (3%) heterotopic ossification resection 5 (7%) PFO 1 (1%) bone grafting of pubis 3 (4%) shelfplasties 2 (3%) arthrotomies 1 (1%) hip fusion	3 (4%) malreduction loss of fixation 1 (1%) femoral nerve dysfunction 2 (3%) malreduction/loss of fixation 1 (1%) pubic nonunion (required surgery) 2 (3%) intraarticular osteotomy 3 (4%) femoral head resubluxation 4 (6%) heterotopic ossification with limitation of flexion Total: 14 (20%)	13 (18%) symptomatic hardware	NA	Major complications all occurred in the first 18 osteotomies
Trumble et al. [31] (1999)	Total: 17 (24%) 6 (5%) PFO 1 (1%) revision surgery for loss of fixation 2 (2%) excision of femoral head osteophytes for impingement 1 (1%) excision of heterotopic ossification 1 (1%) iliac crest bone grafting	3 (3%) arterial thrombosis 2 (2%) DVT 2 (2%) wound infections (required surgery) 1 (1%) loss of fixation after PFO (required surgery) 1 (1%) pubic nonunion and intermittent entrapment of iliopsoas muscle 1 (1%) impending iliac nonunion (bone grafting) 5 (4%) hematoma (surgical treatment) 1 (1%) femoral vein laceration 1 (1%) heterotopic ossification (excised) Total: 17 (14%)	Total: 13 (18%) 31 (25%) symptomatic hardware	20 (16%) heterotopic ossification (Brooker I–II, not excised)	Majority of complications occurred early in the series when the osteotomy was performed through the ilioinguinal approach
	Total: 12 (10%)	Total: 17 (14%)	Total: 31 (25%)	Total: 20 (16%)	

Table 5. continued

Study	Subsequent major surgical procedures other than THA	Major complications	Moderate complications	Minor complications	Learning curve
Sen et al. [26] (2003)	NA	2 (9%) intraarticular osteotomy 1 (4%) malreduction Total: 3 (13%)	1 (4%) fracture posterior column 3 (14%) hematoma Total: 4 (17%)	3 (14%) LFCN dysfunction 2 (9%) heterotopic ossification 3 (14%) superficial infection (nonsurgical treatment) Total: 8 (35%)	Most major complications occurred during learning curve experience
Clohisy et al. [3] (2005)	1 (6%) ORIF of acetabulum resulting from loss of fixation Total: 1 (6%)	1 (6%) loss of fixation (required ORIF) Total: 1 (6%)	1 (6%) asymptomatic ischial nonunion Total: 1 (6%)	2 (12%) pubic nonunion Total: 2 (13%)	The two major complications occurred during learning curve; as experience increases, ability to optimize acetabular reduction has improved
Kralj et al. [15] (2005)	1 (4%) excision of heterotopic ossification Total: 1 (4%) NA	1 (4%) pulmonary embolism 1 (4%) heterotopic ossification (excised) 1 (4%) acetabular fracture Total: 3 (12%) NA	9 (35%) symptomatic hardware 1 (4%) wound hematoma Total: 10 (38%) NA	NA Total: 8 (10%) NA	Not discussed
Cunningham et al. [7] (2006) Peters and Erickson [23] (2006)	1 (1%) revision PAO 1 (1%) bone grafting and fixation of nonunion Total: 2 (2%)	3 (4%) femoral nerve dysfunction 1 (1%) sciatic nerve dysfunction 2 (2%) deep infection 1 (1%) ischial nonunion with pubic nonunion (underwent surgery) 4 (5%) hematoma (treated surgically) 1 (1%) symptomatic pubic nonunion Total: 12 (14%)	NA Total: 10 (38%) NA	8 (10%) pubic nonunion (asymptomatic) Total: 8 (10%)	Not discussed Data reflect a learning curve as all failures and 9 of 11 major complications in series occurred in the first 30 hips

Table 5. continued

Study	Subsequent major surgical procedures other than THA	Major complications	Moderate complications	Minor complications	Learning curve
Biedermann et al. [2] (2008)	NA	1 (2%) femoral head osteonecrosis 2 (3%) acetabular osteonecrosis 5 (8%) major blood loss 4 (7%) Brooker III–IV ectopic bone formation or excision 1 (2%) sciatic nerve dysfunction 5 (8%) peroneal nerve dysfunction 4 (7%) posterior column discontinuity Total: 22 (37%)	3 (5%) hematoma 8 (13%) delayed union or nonunion	9 (15%) Brooker I–II ectopic bone formation 8 (13%) urinary tract infection 11 (18%) postoperative fever 20 (33%) LFCN dysesthesias 9 (15%) secondary wound closure or infection	Acknowledge significance of learning curve
Clohisy et al. [5] (2007)	1 (4%) ORIF, bone grafting for nonunion 2 (8%) labral débridement and osteochondroplasty 1 (4%) PFO 1 (4%) screw exchange Total: 5 (21%)	1 (4%) peroneal nerve dysfunction 1 (4%) femoral nerve dysfunction 1 (4%) symptomatic pubic nonunion (required surgery) Total: 3 (13%)	Total: 11 (18%) NA	Total: 57 (95%) 1 (4%) asymptomatic pubic nonunion 1 (4%) asymptomatic heterotopic ossification Total: 2 (8%)	All complications occurred in the first 11 procedures

LFCN = lateral femoral cutaneous nerve; DVT = deep vein thrombosis; NA = data not available; ORIF = open reduction and internal fixation; PFO = proximal femoral osteotomy; PAO = periacetabular osteotomy.

The main strength of our study relates to the nature of a systematic review in that we were able to assess the available evidence regarding the efficacy of PAO using a rigorous review process. This review has summarized the available evidence regarding this procedure and has identified common findings from different surgeons at different institutions. Despite the predominance of Level IV evidence, there is consensus regarding certain aspects of surgical treatment with PAO. Specifically, multiplanar radiographic correction of dysplastic deformities is achieved reliably, and the technique enables major corrections for severe deformities. Additionally, the clinical benefit of the procedure is optimal in younger patients with no or mild preoperative osteoarthritis. It is less predictable, and failure rates are higher, when preoperative osteoarthritis is graded moderate or advanced. The procedure also is associated with decreased postoperative hip range of motion. Finally, at short- to midterm followup, reduction of pain and enhanced hip function were noted in all studies, yet patients with early failures and/or poor clinical results also were observed. The complication rate is noteworthy with these procedures, as 6% to 37% of patients experienced a major complication. Increased surgeon experience may reduce the complication rate in the future [8]. These studies have not shown long-term survivorship of the reconstruction and have not proven the prevention or delay of secondary osteoarthritis.

Previous studies on alternative acetabular reorientation osteotomies also have investigated factors predictive of outcome [10, 14, 22, 25, 32]. With the rotational acetabular osteotomy, an aspherical femoral head has been associated with hip disease progression after acetabular correction. Studies on the Tönnis triple osteotomy have identified increased age, established osteoarthritis, a lower preoperative functional score, perioperative complications, and postoperative incongruity to be associated with suboptimal clinical results [10, 25, 32]. The clinical effect of deformity correction also should be analyzed. For example, Hailer et al. [10] reported on 61 Tönnis triple osteotomies and found no correlation between acetabular correction and clinical outcome. In contrast, Koga et al. [14] reported on the rotational acetabular osteotomy and observed inferior results with inadequate deformity correction.

Given the lower level of evidence provided by the available studies and the concurrent evolution of surgical techniques, many factors regarding PAO remain unknown. Future studies need to determine optimal selection criteria for surgery, risk factors for clinical failure, optimal deformity correction parameters, the incidence and characteristics of associated complications, and the role of adjunctive surgical procedures (hip arthroscopy, labral and articular cartilage débridement/repair, femoral head-neck

osteochondroplasty, proximal femoral osteotomy, surgical dislocation, and trochanteric advancement). The efficacy of PAO compared with alternative osteotomy techniques, surface replacement arthroplasty, and THA also should be investigated. Therefore, future prospective, longitudinal cohort studies are warranted in which PAO is the main focus. Such studies should be performed by multicenter research groups to facilitate enrollment of large numbers of patients and provide more generalizable data. These studies should use modern, validated, patient-based outcome measures to allow more precise analysis of clinical improvement without bias. More sophisticated predictors of clinical outcome could be established to allow evidence-based decision making preoperatively and at the time of surgery. As additional clinical questions are identified by prospective longitudinal cohort studies, the prospective randomized study design then could be used to resolve these issues.

References

1. Aronson J. Osteoarthritis of the young adult hip: etiology and treatment. *Instr Course Lect.* 1986;35:119–128.
2. Biedermann R, Donnan L, Gabriel A, Wachter R, Krismer M, Behensky H. Complications and patient satisfaction after periacetabular pelvic osteotomy. *Int Orthop.* 2008;32:611–617.
3. Clohisy JC, Barrett SE, Gordon JE, Delgado ED, Schoenecker PL. Periacetabular osteotomy for the treatment of severe acetabular dysplasia. *J Bone Joint Surg Am.* 2005;87:254–259.
4. Clohisy JC, Barrett SE, Gordon JE, Delgado ED, Schoenecker PL. Periacetabular osteotomy in the treatment of severe acetabular dysplasia: surgical technique. *J Bone Joint Surg Am.* 2006;88(1 suppl pt 1):65–83.
5. Clohisy JC, Nunley RM, Curry MC, Schoenecker PL. Periacetabular osteotomy for the treatment of acetabular dysplasia associated with major aspherical femoral head deformities. *J Bone Joint Surg Am.* 2007;89:1417–1423.
6. Crockarell J Jr, Trousdale RT, Cabanela ME, Berry DJ. Early experience and results with the periacetabular osteotomy: the Mayo Clinic experience. *Clin Orthop Relat Res.* 1999;363:45–53.
7. Cunningham T, Jessel R, Zurakowski D, Millis MB, Kim YJ. Delayed gadolinium-enhanced magnetic resonance imaging of cartilage to predict early failure of Bernese periacetabular osteotomy for hip dysplasia. *J Bone Joint Surg Am.* 2006;88:1540–1548.
8. Davey JP, Santore RF. Complications of periacetabular osteotomy. *Clin Orthop Relat Res.* 1999;363:33–37.
9. Ganz R, Klaue K, Vinh TS, Mast JW. A new periacetabular osteotomy for the treatment of hip dysplasias: technique and preliminary results. *Clin Orthop Relat Res.* 1988;232:26–36.
10. Hailer NP, Soykaner L, Ackermann H, Rittmeister M. Triple osteotomy of the pelvis for acetabular dysplasia: age at operation and the incidence of nonunions and other complications influence outcome. *J Bone Joint Surg Br.* 2005;87:1622–1626.
11. Harris WH. Etiology of osteoarthritis of the hip. *Clin Orthop Relat Res.* 1986;213:20–33.
12. Kim YJ, Jaramillo D, Millis MB, Gray ML, Burstein D. Assessment of early osteoarthritis in hip dysplasia with delayed gadolinium-enhanced magnetic resonance imaging of cartilage. *J Bone Joint Surg Am.* 2003;85:1987–1992.

13. Klaue K, Durnin CW, Ganz R. The acetabular rim syndrome: a clinical presentation of dysplasia of the hip. *J Bone Joint Surg Br.* 1991;73:423–429.
14. Koga H, Matsubara M, Suzuki K, Morita S, Muneta T. Factors which affect the progression of osteoarthritis after rotational acetabular osteotomy. *J Bone Joint Surg Br.* 2003;85:963–968.
15. Kralj M, Mavcic B, Antolic V, Igljic A, Kralj-Igljic V. The Bernese periacetabular osteotomy: clinical, radiographic and mechanical 7-15-year follow-up of 26 hips. *Acta Orthop.* 2005;76:833–840.
16. Leunig M, Siebenrock KA, Ganz R. Rationale of periacetabular osteotomy and background work. *J Bone Joint Surg Am.* 2001;83:438–448.
17. Matta JM, Stover MD, Siebenrock K. Periacetabular osteotomy through the Smith-Petersen approach. *Clin Orthop Relat Res.* 1999;363:21–32.
18. Mayo KA, Trumble SJ, Mast JW. Results of periacetabular osteotomy in patients with previous surgery for hip dysplasia. *Clin Orthop Relat Res.* 1999;363:73–80.
19. Millis M, Murphy S, Poss R. Osteotomies about the hip for the prevention and treatment of osteoarthritis. *J Bone Joint Surg Am.* 1995;77:626–647.
20. Murphy SB, Ganz R, Muller ME. The prognosis in untreated dysplasia of the hip: a study of radiographic factors that predict the outcome. *J Bone Joint Surg Am.* 1995;77:985–989.
21. Ninomiya S, Tagawa H. Rotational acetabular osteotomy for the dysplastic hip. *J Bone Joint Surg Am.* 1984;66:430–436.
22. Okano K, Enomoto H, Osaki M, Shindo H. Outcome of rotational acetabular osteotomy for early hip osteoarthritis secondary to dysplasia related to femoral head shape: 49 hips followed for 10–17 years. *Acta Orthop.* 2008;79:12–17.
23. Peters CL, Erickson JA. Treatment of femoro-acetabular impingement with surgical dislocation and debridement in young adults. *J Bone Joint Surg Am.* 2006;88:1735–1741.
24. Salter RB. The classic. Innominate osteotomy in the treatment of congenital dislocation and subluxation of the hip by Robert B. Salter, *J. Bone Joint Surg. (Brit)* 43B:3:518, 1961. *Clin Orthop Relat Res.* 1978;137:2–14.
25. Schramm M, Hohmann D, Radespiel-Troger M, Pitto RP. Treatment of the dysplastic acetabulum with Wagner spherical osteotomy: a study of patients followed for a minimum of twenty years. *J Bone Joint Surg Am.* 2003;85:808–814.
26. Sen C, Asik M, Tozun IR, Sener N, Cinar M. Kotz and Ganz osteotomies in the treatment of adult acetabular dysplasia. *Int Orthop.* 2003;27:78–84.
27. Siebenrock KA, Scholl E, Lottenbach M, Ganz R. Bernese periacetabular osteotomy. *Clin Orthop Relat Res.* 1999;363:9–20.
28. Steel HH. Triple osteotomy of the innominate bone. *J Bone Joint Surg Am.* 1973;55:343–350.
29. Tonnis D, Behrens K, Tscharrani F. A modified technique of the triple pelvic osteotomy: early results. *J Pediatr Orthop.* 1981;1:241–249.
30. Trousdale RT, Ekkernkamp A, Ganz R, Wallrichs SL. Periacetabular and intertrochanteric osteotomy for the treatment of osteoarthritis in dysplastic hips. *J Bone Joint Surg Am.* 1995;77:73–85.
31. Trumble SJ, Mayo KA, Mast JW. The periacetabular osteotomy: minimum 2 year followup in more than 100 hips. *Clin Orthop Relat Res.* 1999;363:54–63.
32. van Hellemond GG, Sonneveld H, Schreuder MH, Kooijman MA, de Kleuver M. Triple osteotomy of the pelvis for acetabular dysplasia: results at a mean follow-up of 15 years. *J Bone Joint Surg Br.* 2005;87:911–915.
33. Wagner H. *Experiences with Spherical Acetabular Osteotomy for the Correction of the Dysplastic Acetabulum.* Berlin, Germany: Springer-Verlag; 1978.